

# **A CASE REPORT ON HERPES SIMPLEX VIRUS ENCEPHALITIS, HERPES ZOSTER SKIN LESION**

## **Abstract**

Herpes Simplex Virus (HSV) encephalitis and Herpes Zoster skin lesions are both caused by different strains of the herpes virus. Herpes Simplex Virus (HSV) encephalitis is caused by the Herpes Simplex Virus (HSV), typically HSV-1, while Herpes Zoster, commonly known as shingles, is caused by the Varicella-Zoster Virus (VZV), which is also a member of the herpesvirus family. This is a case report of HSVE with HZ in a 65 year's old male patient admitted to hospital with chief complaints of erythematous fluid filled rash over abdomen since 1 week, two episodes of generalised type seizures involved all four limbs and with altered sensorium since 1 day. His past medical history revealed that he was a known case of pulmonary tuberculosis (PTB) 2 years ago and taken antitubercular therapy (ATT) for 6 months and also he had developed chickenpox in his childhood. His laboratory tests revealed abnormal haematology and LFT parameters, USG abdomen showed grade 1 fatty changes with hepatomegaly, echogenic sediments in urinary bladder and herpes zoster eruption in dermatomal distribution, chest X-ray showed suggestive sequelae of pulmonary Koch's. the treatment was initiated with Acyclovir, Levetiracetam, Tramadol, etc.

## **Key words**

Herpes simplex virus encephalitis, Herpes zoster, Shingles, Varicella-zoster virus, Herpes skin lesions, Acyclovir, Tuberculosis.

## **Introduction**

### **Herpes simplex virus encephalitis (HSVE)**

It is one of the most common causes of sporadic necrotizing encephalitis globally. The symptoms of HSVE include a sudden onset of fever, headache, altered mental status, convulsions, and localised neurological abnormalities. The brain parenchyma is invaded by the herpes simplex

virus (HSV) either during primary infection or when the latent virus is reactivated, leading to HSVE. Encephalitis is best seen with a magnetic resonance imaging (MRI) scan of the brain, which usually affects the temporal lobe. Polymerase chain reaction (PCR) confirmation of HSVE is achieved when HSV DNA is detected in cerebrospinal fluid (CSF).<sup>1</sup>

Encephalitis caused by HSV is extremely uncommon. Approximately 4 cases per million people are affected, making it the top cause of sporadic encephalitis in the nation. Although the majority of cases of suspected viral encephalitis (60–70%) do not have a known cause, HSV is detected in 35–55 percent of these cases. Serotype 1 (HSV-1) accounts for more than 90% of adult cases, while serotype 2 (HSV-2) is the most common type of herpes encephalitis in newborns and infants. Genetic predisposition of Apolipoprotein ε2 allele overrepresentation is also responsible for HSVE. Isolated cases have been reported after intracranial surgery.<sup>2</sup>

### **Herpes Zoster (HZ)**

It is caused by reactivation of Varicella-zoster virus (VZV). The infection typically presents as two different entities: primary infection is chickenpox which typically occurs in childhood and herpes zoster (HZ) which is the latent manifestation of former infection in the dorsal root and cranial nerve ganglia.<sup>3</sup>

The symptoms of HZ include fever and a rash that starts as maculopapular lesions and then turns into vesicles that spread to the extremities. It has a high rate of transmission. The virus is no longer released from the lesions once the vesicles start to harden. People in their adult years are more likely to have major health problems and experience more difficulties than younger individuals.<sup>4</sup>

The diagnosis includes clinical presentation, neurological symptoms, cerebrospinal fluid (CSF) studies, and imaging abnormalities. The treatment involves the administration of antivirals, which can lead to a complete recovery.<sup>5</sup>

### **Case presentation**

A 65 years old male patient was admitted to Vijayanagar institute of medical science, Ballari (Karnataka) with chief complaints of erythematous fluid filled rash over abdomen since 1 week, two episodes of seizures (generalised type, all four limbs are involved) and with altered

sensorium since 1 day. On examination patient was conscious, not oriented and neck rigidity was positive. R/S- crepts positive.

### Past medical History

He is a known case of pulmonary tuberculosis (PTB) 2 years ago and taken antitubercular therapy (ATT) for 6 months. He had developed chickenpox in his childhood.

### Personal history

Nil habits (non-alcoholic and non-smoker)

**Table 1 :Laboratory Investigations**

Laboratory test	Lab parameters	Results	
		D1	D3
Haematology	Haemoglobin	<b>11.9 g%</b>	<b>11.9</b>
	RBC	<b>4.54 million/cumm</b>	<b>4.6</b>
	WBC	<b>19100 cells/cumm</b>	<b>19900</b>
	Polymorphs (N)	<b>93 %</b>	45
	Lymphocytes (L)	<b>05 %</b>	45
Liver Function Test (LFT)	Total protein	<b>5.0 g/dL</b>	
	Albumin	<b>2.5 g/dL</b>	
	Globulin	2.5	
	A: G	<b>1.0</b>	
	Total bilirubin	1.2 mg/dL	
	Conj. Bilirubin	<b>0.6 mg/dL</b>	
	Unconj. Bilirubin	0.6 mg/dL	
	ALT/ SGPT	29 U/L	
AST/ SGOT	17 U/L		
USG Abdomen and pelvis	<ul style="list-style-type: none"> <li>• Hepatomegaly with grade 1 fatty changes.</li> <li>• Echogenic sediments in urinary bladder.</li> <li>• Herpes zoster eruption in Dermatomal distribution.</li> </ul>		

Chest Xray	<p><b>Right lung:</b> volume loss and large emphysematous bullae</p> <p><b>Left lung:</b> sub pleural emphysematous bullae &amp; compensatory hyper inflation</p> <p><b>Mediastinum &amp; trachea:</b> displaced to right</p> <p><b>Pleura:</b> pleural thickening bilaterally</p> <p>Above features are suggestive of sequelae of pulmonary Koch's.</p>
CT Brain	No significant neuroparenchymal abnormalities are seen.

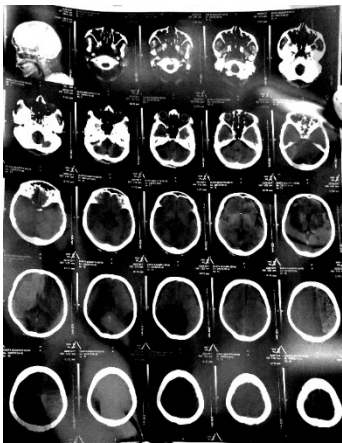


Fig No 1: CT Brain suggestive of no significant neuroparenchymal abnormalities are seen.

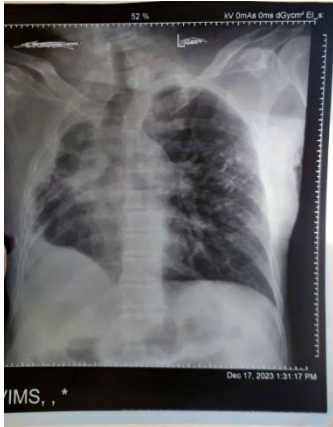

Fig No 2: Chest Xray suggestive of sequelae of pulmonary Koch's.

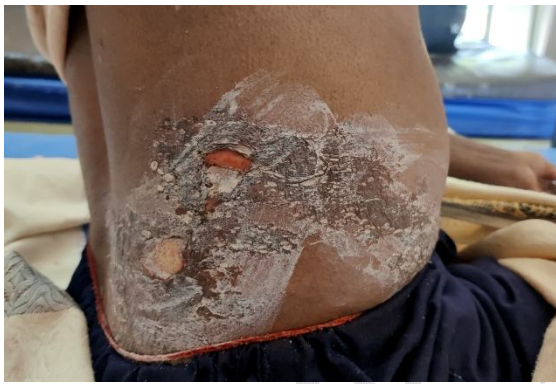

Fig 3

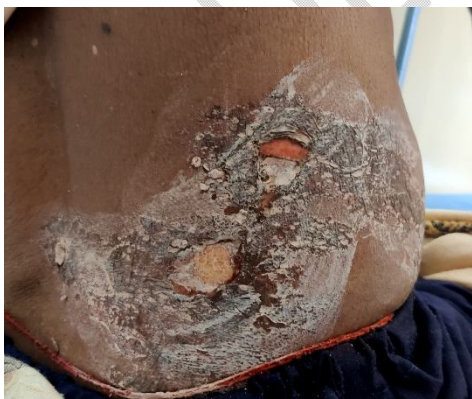

Fig 4

Fig No 3&4: Herpes zoster rash over abdomen in a dermatomal distribution.

Provisional diagnosis: Herpes simplex virus encephalitis, herpes zoster rash with post TB sequelae right lung fibrosis.

**Final diagnosis: Herpes simplex virus encephalitis, herpes zoster skin lesions right abdominal dermatoma (shingles) with post TB sequelae right lung fibrosis.**

**Table 2 :Treatment:**He was started with the following medications

SI No	Name of drugs	Dose	Route	Frequency	Days
1	Ceftriaxone	2g	IV	1-0-1	D1- D5
2	Acyclovir	500mg	IV	1-1-1	D1- D5
3	Dexamethasone	8mg	IV	1-1-1	D1- D5
4	Levetiracetam	1g/ 500mg	IV	Stat/ 1-0-1	D1- D5
5	Pantoprazole	40mg	IV	1-0-0	D1- D5
6	IV Fluids	2-pint NS 1 pint DNS	IV		D1- D5
7	Tramadol	1 amp in 100ml NS	IV	SOS	D2- D5
8	Povidone iodine		Topical	1-1-1	D1- D5

**Table 3 :Discharge medication:**

S.NO	Name of the drug	Dose	Route	Frequency
1	Acyclovir	100mg	PO	1-1-1-1-1
2	Mupirocin ointment		Topical	
3	Zinc calamine lotion		Topical	
4	Tramadol	50mg	PO	1-0-1

## Discussion

Herpes zoster, commonly known as shingles, is caused by the reactivation of the varicella-zoster virus (VZV), the same virus that causes chickenpox. In some cases, VZV can spread to the arteries of the brain and spinal cord, leading to central nervous system complications. These can include acute cerebellar ataxia, herpes encephalitis, vasculopathy, meningitis, myelitis, and facial nerve palsies. After primary varicella infection, the virus enters a latent state within the dorsal root ganglion. Reactivation of the virus leads to inflammation and necrosis of neuronal and non-neuronal cells, resulting in the characteristic dermatomally-distributed vesicular eruption seen in shingles. Prodromal pain often precedes the rash and is thought to stem from neuronal damage caused by the virus. The virus travels along the axons of spinal sensory nerves to reach the skin, where it causes the rash. Reactivation of VZV is believed to occur due to decreased cell-mediated immunity, although the exact factors triggering reactivation are not fully understood.<sup>6</sup>

In this case a 65 years old male patient was with chief complaints of erythematous fluid filled rash over abdomen since 1 week, two episodes of seizures (generalised type, all four limbs are involved) and with altered sensorium since 1 day. His past history reveals that he was a known case of pulmonary tuberculosis (PTB) 2 years back and taken anti tubercular therapy for one year. So based on the patients sign and symptoms the physician has advised him for haematology, liver function test (LFT), USG abdomen and pelvis, chest X-ray and CT brain. In which his Hb, RBC levels were decreased and WBC, polymorph, lymphocytes counts were increased. LFT parameters were abnormal, USG abdomen showed hepatomegaly, grade 1 fatty change, Echogenic sediments in urinary bladder and Herpes zoster eruption in Dermatomal distribution. Chest X-ray showed sequelae of pulmonary Koch's. The treatment was initiated with Acyclovir to treat viral infection (HZ, HSVE), Ceftriaxone to treat nosocomial infection, Dexamethasone to treat infection, Levetiracetam to treat seizures, Pantoprazole to treat gastrointestinal irritation, IV Fluids to maintain fluid & electrolyte balance and Tramadol to treat pain, Povidone iodide to treat lesions present over abdomen.

The patient's diagnosis of "Herpes simplex virus encephalitis" was established through clinical presentation and neurological symptoms such as altered sensorium and seizures. Simultaneously, clinical features including an erythematous fluid-filled rash on the abdomen and findings from an abdominal ultrasound supported the diagnosis of "Herpes zoster." Additionally, the patient was diagnosed with post-TB sequelae based on findings from a chest X-ray.

The patient was discharged from hospital with the following medications, Acyclovir to treat viral infection, mupirocin ointment, zinc calamine lotion to treat herpes skin lesions and tramadol to treat pain and physician advised patient to review after 1 week.

## **Conclusion**

Increasing age correlates with higher incidence and severity of herpes zoster, along with increased risk of postherpetic neuralgia, herpes encephalitis and overall complications. Herpes encephalitis can be deadly if not diagnosed and treated swiftly. In patients with herpes zoster, particularly those who are elderly or immunocompromised, the possibility of herpes encephalitis should be considered if altered mental status is present. Early diagnosis is crucial, as prompt treatment with intravenous acyclovir at least for 7 days can prevent long-term complications and reduce mortality. Any patient with herpes zoster and altered mental status warrants prompt evaluation to prevent central nervous system complications.<sup>6</sup>

## Reference

1. Sili U, Kaya A, Mert A, HSV Encephalitis Study Group. Herpes simplex virus encephalitis: clinical manifestations, diagnosis and outcome in 106 adult patients. *Journal of Clinical Virology*. 2014 Jun 1;60(2):112-8.
2. Tyler KL. Update on herpes simplex encephalitis. *Rev Neurol Dis*. 2004 Jan 1;1(4):169-78.
3. Le N, Razick DI, Dhaliwal A, Akhtar M, Daniel E. A Rare Case of Varicella-Zoster Virus Encephalitis Presenting With Lost Ability to Play the Piano in an Immunocompetent Pediatric Patient. *Cureus*. 2023 Jul 5;15
4. Nguong LT, Zia S, Jha SB, Isufi M, Elsheikh SA. Case Report of Herpes Zoster in the 17-year-old Boy.
5. Rodrigues F, Santos M, Macedo E, Rocha JM, Silva L, Oliveira AS, Alves J, Apolinário I, da Silva LN, Oliveira Sr AS. Varicella-Zoster Virus: A Case of Encephalitis. *Cureus*. 2023 Sep 16;15
6. Ellis DL, Barsell A, Riahi RR, Stumpf B. Varicella zoster virus encephalitis in a patient with disseminated herpes zoster: report and review of the literature. *Dermatology online journal*. 2015;21(3).